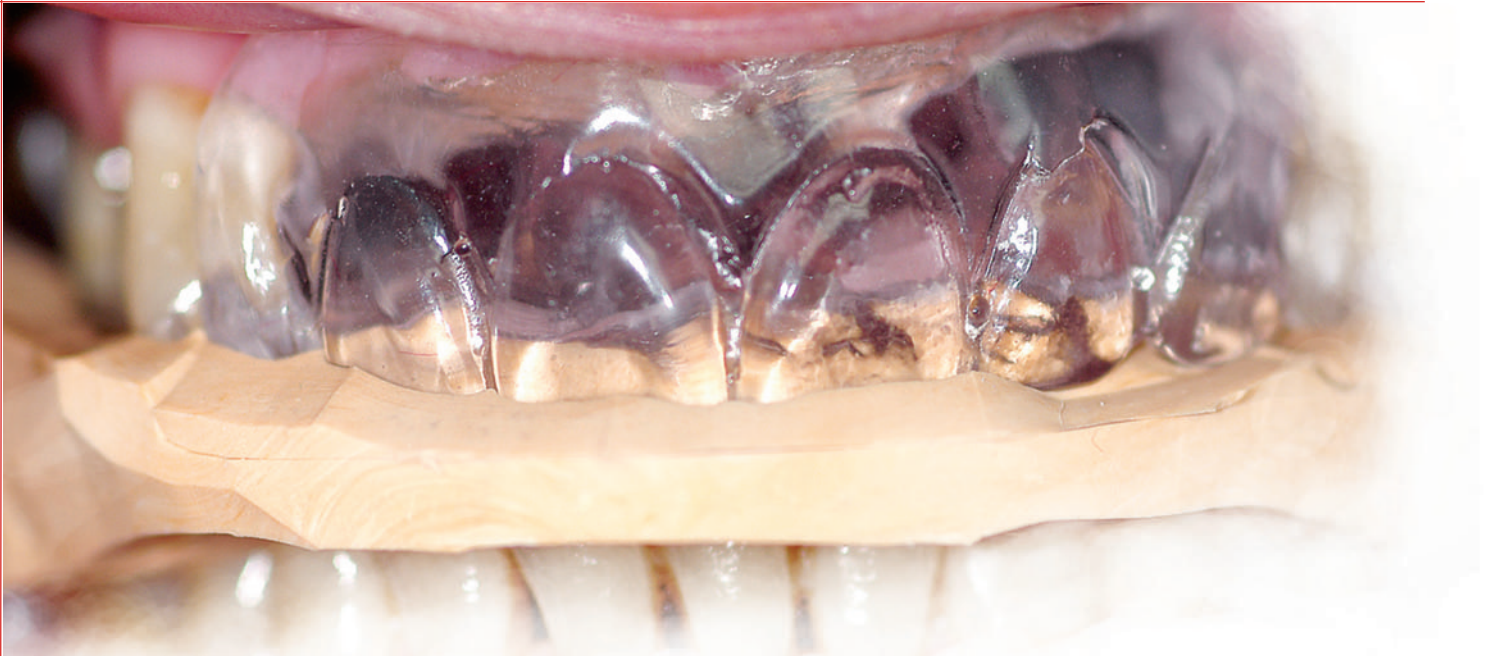



# Another Implant Option for Missing Teeth with Challenging Symmetry

Patrick Gannon, DDS and Luke Kahng, CDT

## Introduction

A 58 year old male had been missing teeth #7=12 for approximately 28 years. During that time, he had been wearing a removable partial denture. The patient had become extremely self-conscious about having to wear a removable appliance, uncomfortable with the palatal extension, and the visible partial denture clasps. For these reasons, the patient sought a fixed solution to replace his RPD.

The maxillary midline of the partial denture was off. For symmetry and proportional purposes, we had to consider adding one tooth in the final restorative process. After the discussion among the clinician, patient and technician, it was decided that for best results, an additional tooth would be included in order to correct the problem.

## Clinical Exam

The patient presented with teeth #7=12 missing. The periodontal status of the remaining teeth was stable, but they were poor candidates to support a fixed partial denture due to previous bone loss, and the extent of the

edentulous span. The edentulous space had resorbed vertically and palatally. There were concavities in the buccal plate, causing a potential compromise in implant placement.

The periodontium was stable and relatively healthy. Periodontal probing revealed some isolated 4mm pockets. The tissue was pink, firm, and otherwise healthy.

The patient's medical history was non-contributory, with only seasonal allergies being noted.

## Radiographic Examination

Radiographs showed sufficient vertical bone to place implants. The clinical presence of buccal concavities was a cause for concern with optimal implant location. As a result, it was determined that the case would be treated utilizing a CT scan in conjunction with NobelBiocare's Procera Software Planning System. Analysis of the case with the NobelBiocare's software revealed sufficient bone for placement, as well as the ability to place them in an acceptable location, given the circumstances.

## Case Study

Diagnostic casts were taken with 3M Permadyne Penta H tray material and Permadyne Garant 2:1 wash material in an auto mix syringe. A permanent impression material was chosen over alginate in order to obtain models with maximum dimensional stability. These models would be used in the fabrication of the radiographic guide, so accuracy was critical. The models were mounted using a facebow transfer and a centric bite registration on a Denar articulator.

Denture teeth were set in wax on a processed denture base. The processed base was necessary because this would be the template used in the fabrication of the radiographic guide and ultimately, the fabrication of the computer-generated surgical guide. The setup was evaluated to assess occlusion, lip support, tooth position, esthetics, and patient approval.

The setup was duplicated in clear acrylic resin. An omnivac stent was made over the acrylic setup on the model as a means of blocking out undercuts in the fabrication of the radiographic guide. (Fig. 1). "Windows" in the omnivac stent were made over the cusps of two

teeth on each side of the arch. These would serve as "stops" to ensure full seating of the radiographic guide. Primo Splint material was placed over the area of remaining teeth and onto the stone model that protruded through the previously made windows. A portion of the Primo Splint material was removed where the windows were placed so that the full seating of the guide could be assessed on the model. The block out omnivac material was removed, leaving only the acrylic duplicate and the Primo Splint material.

A bite registration was taken with the radiographic guide to ensure that the guide was stable and positioned correctly for the CT scan (Fig. 2).

The information from the CT scan was transferred to the NobelBiocare Procera Software. Implant location was determined on the basis of maximizing available bone and placing the implants in the best position available relative to tooth position. Using the Nobel Guide, four Nobel Replace 3.5mm internal connection implants were placed (Fig. 3), and covered with healing caps. Immediate loading was not chosen as an option due to lack of cross arch stability, the length of the edentulous span in a relatively straight line, and the inability to control

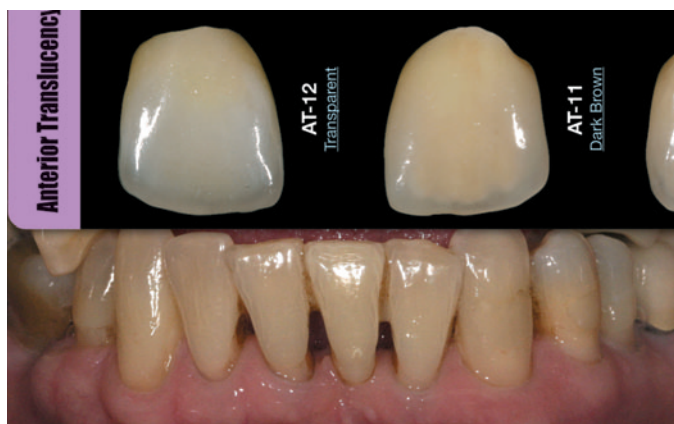

Fig. 1: The study cast was used to make the radiographic guide.




Fig. 2: The centric bite record in place for the CT scan.

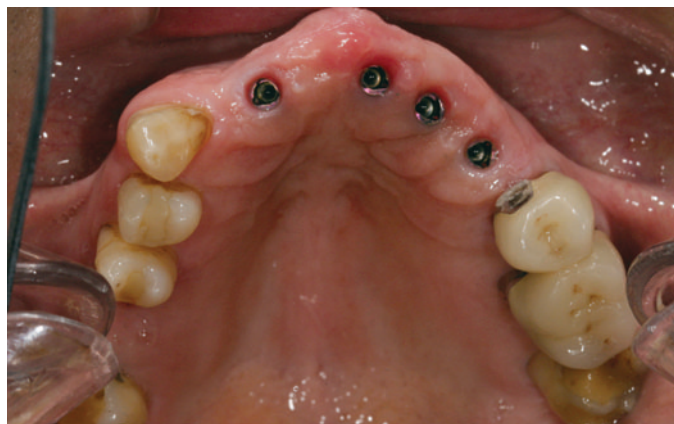

Fig. 3: Maxillary occlusal view of the implant position.

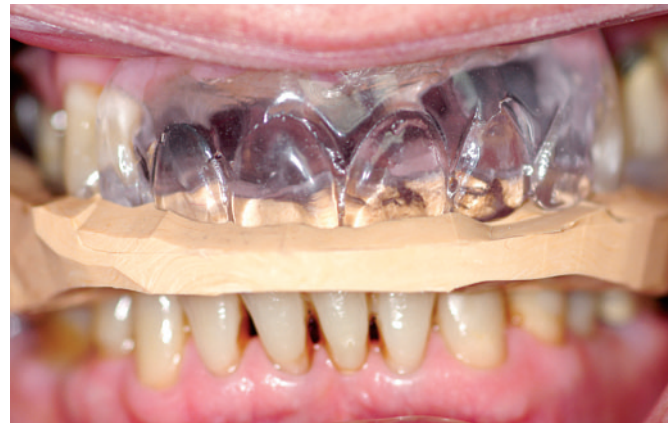

Fig. 4: The patient's Anterior Translucency is checked using the LSK Chair Side Shade Selection Guide.

occlusal forces. The patient wore his existing RPD during the six month healing phase.

After integration, a fixture level open tray impression was taken. NobelBiocare titanium temporary abutments were placed and luted together using GC resin and carbide burs. By luting the abutments together, a more precise recording of the relationship of each implant seating surface to the others was obtained. Two models were poured. The first one in impression plaster captured only the implants. This would be used as the scanning model for bridge fabrication. The second model was a soft tissue model using Zhermack Rigid and green stone, capturing all the detail of the soft and hard tissue structures. The soft tissue model was mounted on the Denar articulator and sent to the lab for fabrication of a six unit Procera bridge on zirconia abutments.

## Laboratory Procedures

With the LSK121 Chair Side Shade Selection Guide, the patient's anterior translucency is checked as part of the custom shading procedure (Fig. 4). Using the study cast

model as a guide, the case was analyzed to determine ideal tooth position. Concerns the patient and doctor may have about the final restoration can be addressed during the planning stage. The implant positioning and placement must be compatible with the patient's tooth position when the final restoration is delivered or the case will not be acceptable. An occlusal view of the maxillary palate provides a clear view of implant placement. With new scanning technology, the implants can be placed in the most ideal location possible. (Fig. 3). Any questions related to the patient's occlusion and tooth position are addressed in the study model analysis and help determine how the final restoration will be made.

A full contour wax-up was fabricated to assess esthetics and occlusion. Due to the midline discrepancy in the partial denture, it was determined that tooth size and proportion needed to be changed by the addition of an extra tooth in order to correct the esthetic problem (Fig. 5).

The Nobel Biocare Forte scanning unit allows for an exact passive fit in the final restoration (Fig. 6). The side

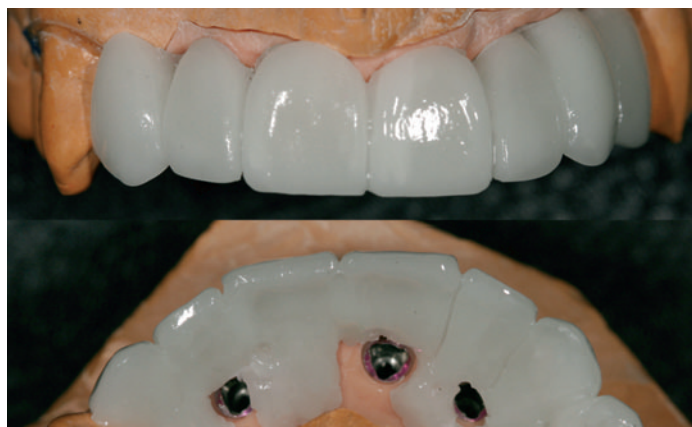

Fig. 5: The 7 unit wax-up was created with two left canines in order to correct the midline discrepancy and satisfy esthetic demands.




Fig. 6: With the Nobel Biocare Forte Scanning System, the technician can scan the position locator.

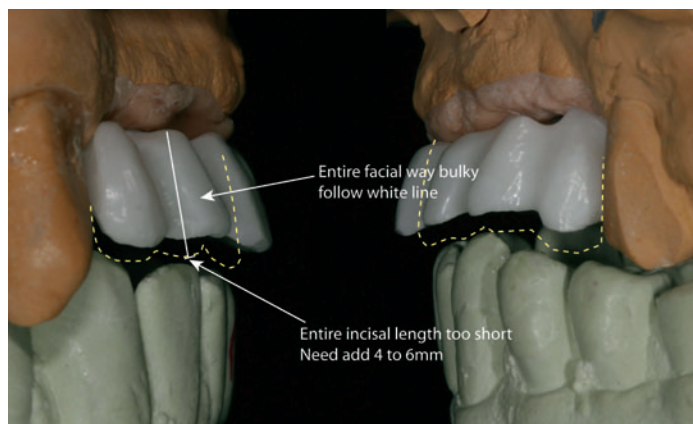


Fig. 7: Side view of the frame design for communication purposes.

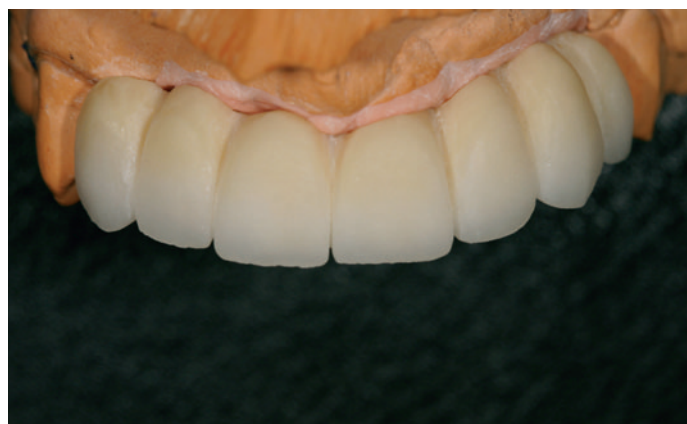

Fig. 8: Bisque bake stage.

views of the frame design aids the technician with communication between the doctor and the lab – pinpointing what he thinks should be addressed to plan the final frame design (Fig. 7). Final contours are checked in the bisque bake stage (Fig. 8) prior to the application of the gingival porcelain. A custom porcelain shade was mixed to match the patient's gingival tissues (Fig. 9) and applied to the model to create natural contours (Fig. 10). With the third porcelain build-up complete, the crowns are ready for firing (Fig.11).



Fig. 9: The porcelain was mixed to create a custom pink color to match the patient's gingiva.

The 7-unit ceramic zirconia implant bridge, prepared with GC Initial porcelain, is ready for delivery (Fig. 12). A lingual view shows the screw access holes and their relationship to the clinical crowns (Fig.13). A side view of the bridge in the mouth (Fig. 14) demonstrates its natural and harmonious blending with the adjacent teeth. A retracted facial (Fig. 15) and relaxed side view (Fig. 16) demonstrate the compatibility the patient now has with his lip support, tooth contours, occlusion, and esthetics.

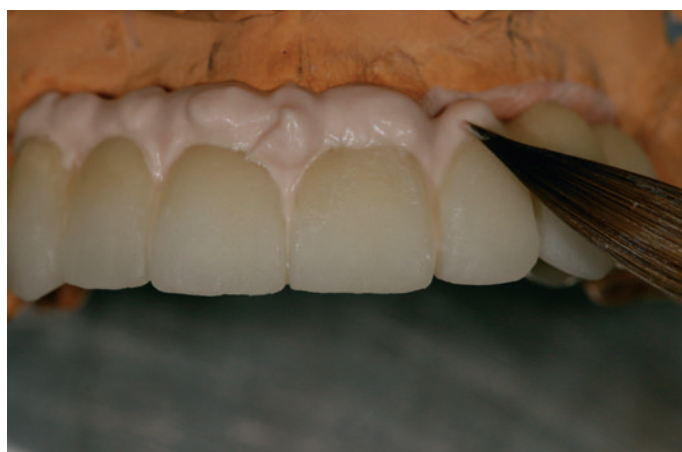

Fig. 10: Pink porcelain is applied to the model.

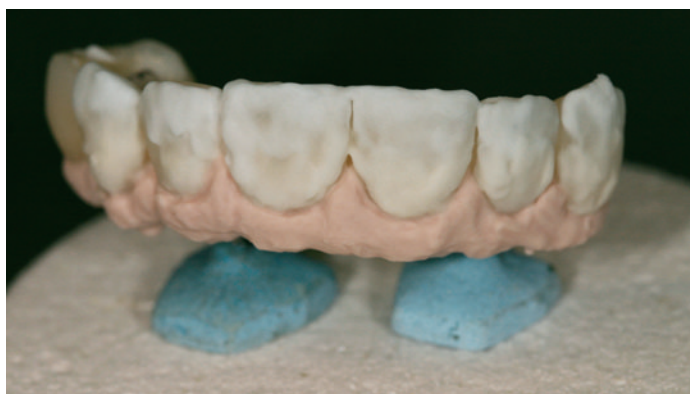

Fig. 11: After the third porcelain build-up, the bridge is ready for firing.

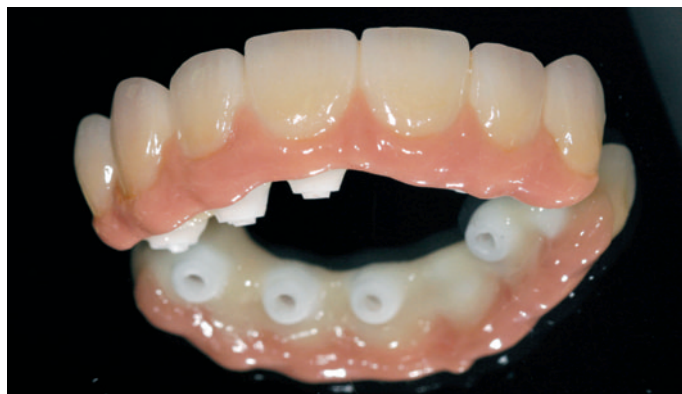

Fig. 12: The ceramic implant bridge is finished and ready for delivery.

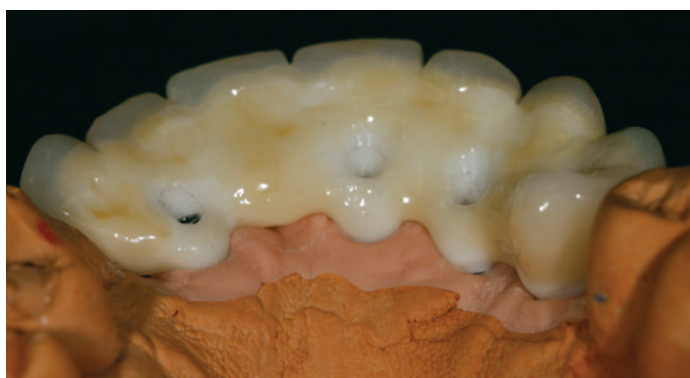

Fig. 13: Finished product, lingual view. The porcelain was created with greater thickness on the lingual to account for screw access location.

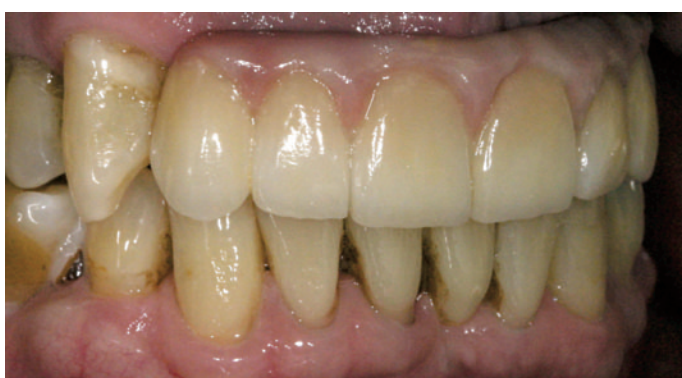

Fig. 14: Side view portrait – note the blended color of the pink gum tissue.

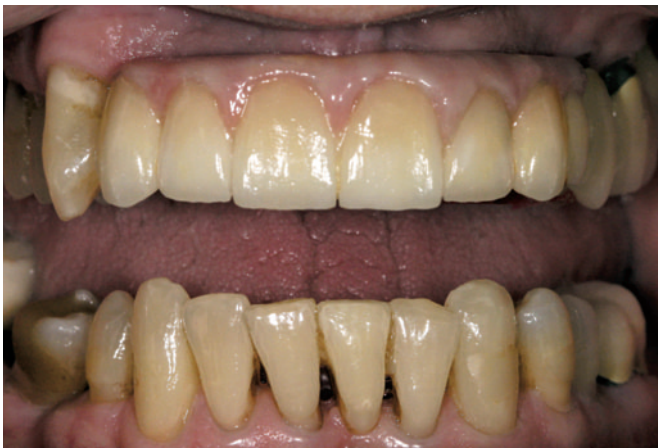

Fig. 15: After delivery, a facial view.

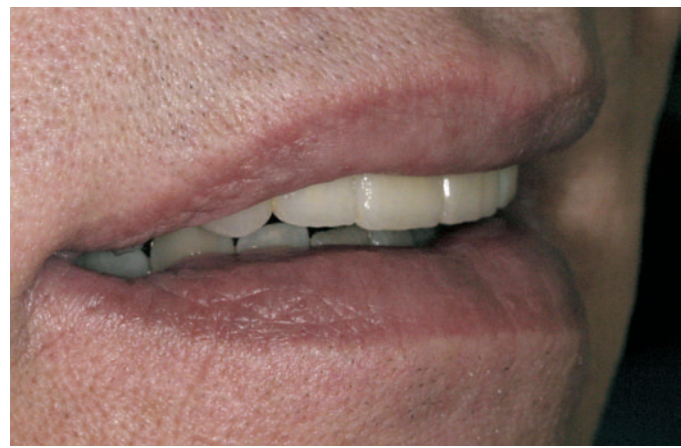

Fig. 16: Rest position, side view.

## Conclusion

The difference a patient will feel in his overall confidence after a removable appliance is replaced with a fixed implant bridge can make a dramatic difference when a person is no longer afraid or embarrassed about the limitations of the RPD or the appearance of his

smile. Dental implants have opened up new and endless possibilities for patients with missing teeth, as we have demonstrated in this text. Treatment planning, technology and artistry all come together to make one beautiful result when the dentist, patient and technician work as a team to create a lasting and functional smile.

### About the Author



**Patrick Gannon, DDS.** Dr. Gannon received his degree from the University of Illinois College of Dentistry. He has been involved with implants for over twenty-three years, keeping up with the latest technology and procedures as they evolve. Dr. Gannon has presented on the subject of All-on-Four technique, Nobel Guide prosthetics, and full arch fixed implant prosthetics. He maintains a full-time general/restorative private practice in Palos Heights, Illinois. [patrickgannon@ameritech.net](mailto:patrickgannon@ameritech.net)



**Luke Kahng, CDT,** is the owner of LSK121 Oral Prosthetics, a dental laboratory. He has published over 35 articles in major dental publications. He is the author of the recently published *Anatomy from Nature*, with 50 illustrated pages of full contour wax-ups, stone models and porcelain teeth, all re-created using natural teeth as a guide. His new *Esthetic Guide Book* features 31 patient cases from a single anterior tooth to a full mouth reconstruction. He invented the *Chair Side Shade Selection Guide* featuring over 150 zirconia fabricated restorations based on patient enamel and translucency research, with patent pending. If you would like to contact him, his email address is: [luke@lsk121.com](mailto:luke@lsk121.com) or visit [www.lsk121.com](http://www.lsk121.com)



## INCISAL EDGE DENTAL LABORATORY

### *Cosmetics Without Compromise*

Certified laboratory for CAPTEK, CRISTOBAL+, IPS EMPRESS, IPS E-MAX, PROCERA, ATTACHMENTS, IMPLANTS, CUSTOM IMPLANT ABUTMENTS & LASER WELDING.

Looking after all of your Dental Laboratory needs.  
We pride ourselves on quality work, great service and exceptional value.

Thomas Kitsos, RDT #92184

3410 Yonge Street • Toronto, Ontario • M4N 2M9

Tel: (416) 806-9057 • 1-877-INCISAL • Fax: (416) 489-6541